

Isolated Repair of the Medial Patellofemoral Ligament in Primary Dislocation of the Patella: A Prospective Randomized Study

Svend Erik Christiansen, M.D., Bent Wulff Jakobsen, M.D., Bent Lund, M.D., and Martin Lind, M.D., Ph.D.

Purpose: The purpose of this study was to evaluate the effect of surgical reinsertion of the medial patellofemoral ligament (MPFL) to the adductor tubercle compared with conservative treatment in patients with primary dislocation of the patella. **Methods:** Eighty patients with primary patella dislocation were included in the study. Delayed arthroscopy (mean, 50 days after injury) was performed to assess cartilage injury and status. During arthroscopy, patients were randomized to surgical reinsertion of the MPFL or to conservative treatment. Conservative treatment was use of a brace with 0° to 20° motion for the first 2 weeks after dislocation. Patients were followed up for 2 years. The incidence of recurrent patella dislocation was recorded along with the clinical Kujala scores and Knee Injury and Osteoarthritis Outcome Scores. **Results:** The redislocation rates were 17% and 20% in the operative and conservative treatment groups, respectively ($P =$ not significant). Kujala scores were 85 and 78 in the operative and conservative treatment groups, respectively ($P = .07$). The patella stability subscore was significantly higher in the operative group. No difference in Knee Injury and Osteoarthritis Outcome Scores was found. **Conclusions:** Delayed primary repair of the MPFL by use of an anchor-based reattachment to the adductor tubercle without vastus medialis obliquus repair after primary patella dislocation does not reduce the risk of redislocation nor does it produce any significantly better subjective functional outcome based on the Kujala knee score. Only the specific subjective patella stability score was improved by MPFL repair compared with conservative treatment. **Level of Evidence:** Level I, therapeutic randomized controlled trial. **Key Words:** Patella dislocation—Medial patellofemoral ligament—Surgical repair—Randomized controlled trial—Patellar instability.

PPrimary dislocation of the patella (PDP) is a severe injury to the knee normally resulting in “giving way,” severe pain, and a sensation of lateral displace-

ment of the patella. Normally, an intra-articular hematoma will develop within a short time and the medial epicondyle will be tender. Subsequent spontaneous repositioning of the patella can interfere with the diagnosis in the emergency department. Arthroscopic pathoanatomic findings include hematoma and chondral or osteochondral lesions, often located on the central or medial facet of the patella or on the lateral condyle. Typically, a lesion on the distal part of the medial patella retinaculum can also be seen arthroscopically.

Radiographs can show intra-articular hematoma, and often, small avulsions are seen at the medial border of the patella. These avulsions are seldom seen arthroscopically and seem to represent lesion to the distal part of the medial retinaculum (the medial patel-

From the Division of Sportstrauma, Orthopaedic Department E, Aarhus University Hospital, Aarhus, Denmark.

Recipient of the Patellofemoral Excellence Award at the International Society of Arthroscopy, Knee Surgery and Orthopaedic Sports Medicine 2007 meeting, Florence, Italy.

The authors report no conflict of interest.

Received November 29, 2007; accepted March 13, 2008.

Address correspondence and reprint requests to Martin Lind, M.D., Ph.D., Division of Sportstrauma, Orthopaedic Department E, Aarhus University Hospital, Tage Hansen Gade, 8000 Aarhus C, Denmark. E-mail: martinlind@dadlnet.dk

© 2008 by the Arthroscopy Association of North America

0749-8063/08/2408-7602\$34.00/0

doi:10.1016/j.arthro.2008.03.012

lotibial/meniscal ligament). Magnetic resonance imaging shows bone bruise in the patella, and in the lateral femoral condyle, chondral and osteochondral lesions are normally seen. Further lesions to the medial patellofemoral ligament (MPFL) can be found in almost 100% of the cases.¹

The MPFL is a thin ligament that inserts at the proximal two thirds of the medial border of the patella. Some of the fibers fuse with the vastus medialis obliquus (VMO) aponeurosis. At the femur, the ligament inserts medial at the adductor tubercle (AT) proximal to the insertion of the medial collateral ligament and distal to the insertion of the adductor magnus tendon.

Several studies have shown that the MPFL is the primary constraint in preventing lateralization of the patella.^{2,3} Other studies have described how, after dislocation, the MPFL does not reinsert, which leads to chronic patellar instability. Another important issue is that not only is the MPFL detached from the AT, but it seems that the whole complex of the MPFL and the insertion of the VMO to the intramuscular septum and insertions to the medial border of the femur is disrupted as a result of PDP. This might lead to a more cephalad dynamic action of the VMO.⁴⁻⁶ This, combined with the loss of the medial constraint of the MPFL, can lead to permanent patellar instability. Several studies have shown that untreated PDP leads to complications in between 40% and 60% of cases.⁷ Complications include secondary patellar instability (recurrent dislocation or subluxation) and/or anterior knee pain due to cartilage lesions.^{8,9}

A major controversy is whether surgical treatment can improve clinical outcome after PDP.¹⁰ The need for surgical intervention is clearly different after PDP compared with the patient with chronic patellar instability.^{11,12} On the basis of the aforementioned patho-anatomic considerations, several investigators have described the results of performing surgical reinsertion of the MPFL at the AT after PDP.^{4,13} These small case series showed good results in terms of redislocations. Only 1 randomized controlled study exists, and in that study no effect of medial retinaculum repair could be found.¹⁴

In patella dislocation the MPFL is injured in more than 90% of cases, and the point of injury is the femoral attachment site.^{1,4} This could indicate that repair and reinsertion of the MPFL at the AT, which is the insertion site of the MPFL, would comprise a reasonable surgical treatment. The purpose of this prospective randomized study was to evaluate the effect of delayed surgical reinsertion of the MPFL

compared with conservative treatment in patients with PDP. We hypothesized that surgical reinsertion of the MPFL to the AT would result in better clinical results than conservative treatment based on Kujala knee score and/or the patella redislocation rate.

METHODS

Design

The study was a prospective, randomized, controlled clinical trial. The patients were randomized to either conservative treatment or delayed operative reinsertion of the MPFL at the AT for treatment of primary patella dislocation. Patients randomized to conservative treatment received no further treatment or brace usage. We have designated the group that had initial treatment with a brace and subsequent arthroscopy with repair as the operative group and the group that had initial treatment with a brace and subsequent arthroscopy without repair as the conservative treatment group. Inclusion and exclusion criteria are shown in Table 1. The patients were followed up for 2 years, at which point follow-up ceased. The study was approved by the local ethical committee.

Patients admitted to the emergency department at the Aarhus University Hospital in Aarhus, Denmark (a city of approximately 250,000 inhabitants), in the period from April 1998 until September 2002 were candidates for study inclusion. The diagnosis of primary patella dislocation was either a locked dislocated patella or a history of acute knee trauma, intra-articular hematoma, tenderness on the medial epicondyle, and positive lateral patella apprehension. A knee brace with a range of motion of 0° to 20° was used until surgery or for 2 weeks after the diagnosis was made in the emergency department.

Patients were referred from the emergency department to the Division of Sportstrauma, where they were asked to participate in the study and prepared for surgery. In most cases patients were referred to a physiotherapist in case of knee mobility problems preoperatively. All patients first underwent arthros-

TABLE 1. Inclusion and Exclusion Criteria

Inclusion criteria	
Patients with first-time dislocation of patella	
Patients aged between 13 and 30 yr	
Exclusion criteria	
Patients with history of patellofemoral instability or pain	
Patients who were unable to follow treatment regimen	

copy for intra-articular evaluation and were subsequently randomized to either further surgical treatment with MPFL reinsertion or no further surgical treatment. The arthroscopy was performed, on average, 50 days after the patella dislocation.

Surgery

An initial arthroscopy was performed. Osteochondral fragments were fixed with resorbable pins if possible. Otherwise, they were removed with debridement of the cartilage lesions. At this point, the patients were randomized to repair or nonoperative treatment of the MPFL. A 5- to 7-cm incision was made over the AT. The superficial layer was incised parallel to the fiber direction over the tubercle and reflected. With the knee in flexion, a small incision was made over the AT in the vastus medius aponeurosis, approximately 1 cm from the border of muscle. With the knee in extension, the MPFL insertion site at the AT was identified medial to the VMO and anterior and distal to the adductor magnus insertion. To avoid overconstraining of the ligament, tension was secured in the whole range of motion before reinsertion. The MPFL was reinserted at the AT with 2 Mitek G2 anchors (DePuy Mitek, Raynham, MA). The sutures were placed by use of a baseball stitch up in the more well-defined patella near part of the ligament (Fig 1). No repair to the VMO, adductor magnus tendon, or intermuscular septum was performed. No lateral release or distal realignment procedures have been performed in any patient. All procedures were performed or supervised by the same surgeon (S.E.C.).

All patients with MPFL repair underwent the same postoperative rehabilitation protocol. From weeks 0 to 2, they used arm crutches and a knee brace with 0° to 20° of motion, and full weight bearing was allowed. From weeks 2 to 6, they had free range of motion and performed increased quadriceps exercises in combination with general physiotherapy. Clinical follow-up was performed after 2 weeks, 6 weeks, 1 year, and 2 years.

End-points

The primary end-point was the incidence of redislocation within 2 years from inclusion. The clinical outcome was evaluated by subjective clinical assessments by use of the Kujala score and Knee Injury and Osteoarthritis Outcome Score (KOOS) at 2 years. Radiographic preoperative investigations included the following projections: anteroposterior, lateral, and patella skyline a.m.; Merchant; femoral trochlear sulcus

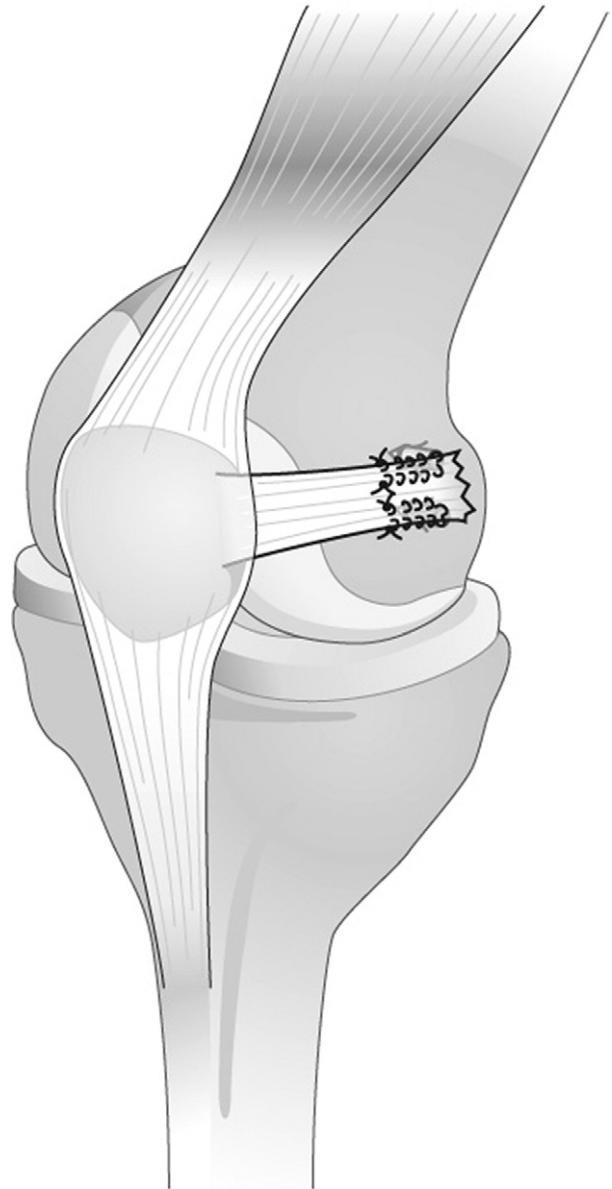


FIGURE 1. In the surgically treated group, the MPFL was isolated and repaired by sutures fixed in the medial femoral condyle by metal anchors.

angle; congruency angle; patella typing (Wiberg); and patella alta index using the Insall-Salvati ratios were determined for further correlation analyses to clinical outcome.

Statistics

Randomization between surgery and conservative treatment was performed by random drawing of 100 envelopes. Study group size was based on the follow-

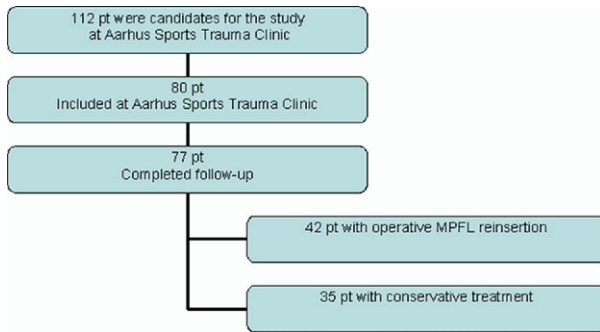


FIGURE 2. Patient (pt) flow in our randomized trial.

ing power calculations. The expected rate of redislocation was 30% in the conservative treatment group and 5% in the operative group; thus, for a power of 0.80, a group size of 39 was required. Regarding the Kujala score, the minimal relevant difference in score between groups was 10, with an expected SD in Kujala score of 15; thus, for a power of 0.80, a group size of 37 was required. A group size of 40 was chosen for the study. Differences in redislocation rates between groups were compared by use of the χ^2 test, and differences in Kujala scores were compared by use of the Mann-Whitney test. KOOS subscores were compared by use of analysis of variance test.

RESULTS

In the inclusion period 112 patients were admitted to the Division of Sportstrauma with primary patella dislocation; 80 patients were included in the study, and 77 completed final follow-up. Randomization resulted in 42 patients in the operative group and 35 in the conservative treatment group. The mean delay from injury to surgery was 50 days. Patient flow in the study is shown in Figure 2. The 32 patients not included in the study declined to participate. They were treated with arthroscopy if radiographic examination led the clinician to suspect osteochondral fracture; otherwise, they received conservative treatment.

The epidemiologic data showed no difference be-

tween the 2 groups with respect to gender, body mass index, or age (Table 2). Furthermore, no difference between the groups could be found with respect to hyperlaxity, femoropatellar dysplasia, or patella alta (Table 3). At arthroscopy, no differences in the extent of intra-articular cartilage lesions were seen between the groups. Chondral injury without osteochondral fracture defined as International Cartilage Repair Society injury grade 2 to 4 was seen on the patella in 24% of cases (17/72) and on the trochlea in 7% of cases (5/72). Of the 10 osteochondral lesions found, only 2 were suitable for refixation (Table 3). This was done in both cases in an open manner with resorbable pins. There was 1 refixation in each treatment group. Two meniscus lesions were found during arthroscopy. In both cases it was a contusion lesion of the lateral meniscus, and in both cases debridement with a shaver was performed.

The redislocation rate was 16.7% in the operative group and 20% in the conservative treatment group at 2 years' follow-up, with no significant difference between the groups (Table 4). A survival analysis of the time of redislocation showed that patients in the conservative treatment group dislocated slightly earlier than the operated patients, but at no time point was any statistical difference found (Fig 3).

The results from the Kujala score and KOOS assessments did not show any significant difference between the groups (Table 4). A tendency toward an improved Kujala score was found for operated patients, with a score of 85 in the operative group versus 78 in the conservative group at 2 years' follow-up ($P = .07$). The patellar instability subscore of the Kujala score (question 9; range, 0 to 10 points) was significantly higher in the operative group (median, 10; range, 6 to 10), whereas the median in the conservative group was 6 (range, 4 to 6) ($P = .007$).

DISCUSSION

Biomechanical studies have shown that the MPFL is the primary passive restraint to lateral displacement/dislocation of the patella. Similar studies have shown

TABLE 2. Basic Epidemiologic Data

	Operative Group	Conservative Group	Patients Not Included
Male/female	24/18	18/17	11/14
Right side/left side	19/23	19/16	12/13
Age (yr) [mean (range)]	20.0 (14-30)	19.9 (13-39)	19.2 (14-39)
Body mass index [mean (SD)]	22.6 (3.1)	22.2 (4.1)	22.6 (3.5)

TABLE 3. Radiology and Intra-articular Lesions

	Operative Group	Conservative Group	Patients With Redislocation
Hyperlaxity (>5° hyperextension)	19/42	8/35	6/14
Patella dysplasia (Wiberg types B and C)	32/42	23/35	10/14
Trochlear sulcus angle (°) [mean (SD)]	141 (9.1)	139 (8.8)	145 (9.1)
Patella index >1.2	19/42	10/35	8/14
Osteochondral fracture	7/42	3/35	3/14
Meniscus lesions	2/42	0/35	0/14
Quadriceps angle (°) [mean (SD)]	14.0 (3.0)	12.9 (4.3)	13.7 (3.4)

NOTE. Data are presented as number of patients, unless otherwise indicated. Predisposing factors such as hyperlaxity, patella dysplasia, and patella alta in the 2 treatment groups and in the patients who redislocated within 2 years are shown. Arthroscopic findings concerning incidence of osteochondral fractures and meniscus lesions are also presented, along with preoperative clinically determined quadriceps angles. All data were tested for differences between operative group and conservative treatment group and between patients with redislocation and those without redislocation, and no significant differences were found.

that the patella cannot be brought in a dislocation position without rupture of the MPFL.¹⁵ Finally, the injury to the MPFL is almost always close to or at the AT.^{1,16,17} According to these observations, it seems reasonable to repair the ligament at the AT after PDP.

Previous studies have reported varying results after surgical treatment for PDP. Ahmad et al.¹³ in a small case series found an excellent Kujala score (92%) and no redislocations. In their study both the MPFL and the VMO were repaired to normal anatomic positions. However, subluxation occurred in 2 of the 8 included patients. Other case series with good results have been presented.⁴ Only 1 randomized controlled study with a relatively high number of patients exists.¹⁴ The results are in accordance with the results from our study: surgical treatment did not improve clinical results after PDP. The combined redislocation and chronic subluxation rates were 25% and 36% in the operative and conservatively treated groups, respectively. However, the surgical procedures in their study did not address MPFL repair but instead various medial retinaculum procedures, which were combined in most of their cases with a lateral release.¹⁴ The difference in

surgical procedures makes it impossible to compare the study by Nikku et al.¹⁴ with our study. As observed for many other surgical treatments, the results from MPFL repair case series seem to overestimate success rates when compared with randomized trials.

This study, which was a randomized prospective study with 80 patients and 2 years' follow-up, found no advantage to performing a primary delayed reinsertion of the MPFL with respect to redislocation or subjective knee function. However, a tendency toward improved Kujala score in the operative group was found ($P = .07$), and the subscore regarding patella stability within the Kujala score was significantly better in the operative group. This result indicates that the subjective sensation of patella stability was improved by surgical repair of the MPFL. The lack of improvement in the redislocation rate indicates that the repaired ligament is not strong enough to withstand new trauma that lateralizes the patella.

The VMO fiber direction and anatomic relation with the intermuscular septum proximally, as well as the adductor magnus tendon distally, provide the VMO with the ability to pull the patella in an oblique direc-

TABLE 4. Redislocation Rate, Kujala Score, and KOOS

	Operative Group	Conservative Group	Statistics
Redislocation rate [No. of patients]	7/42 (16.7%)	7/35 (20%)	$P = NS (\chi^2)$
Kujala score [mean (SD)]	84.6 (17.5)	78.1 (15.9)	$P = .07$ (Mann-Whitney)
Patellar instability score [median (range)]	10 (6-10)	6 (4-6)	$P < .01$ (Mann-Whitney)
KOOS score [mean (SD)]			
Symptoms	80.9 (17.4)	80.2 (15.9)	$P = NS$ (ANOVA)
Pain	95.5 (6.9)	92.3 (7.9)	$P = NS$ (ANOVA)
ADL	94.7 (10.3)	91.1 (9.8)	$P = NS$ (ANOVA)
Sports and recreation	87.2 (11.1)	83.6 (11.4)	$P = NS$ (ANOVA)
Quality of life	90.4 (8.9)	87.7 (9.7)	$P = NS$ (ANOVA)

Abbreviation: NS, not significant; ANOVA, analysis of variance; ADL, activities of daily living.

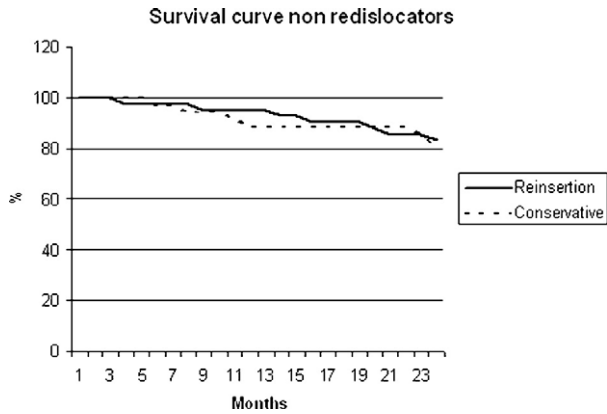


FIGURE 3. Kaplan-Maier survival curve of patients without redislocation during 2 years of follow-up.

tion and thus to work as a medial dynamic stabilizer to the patella.^{5,18} In addition, Goh et al.¹⁹ have shown in a cadaveric study that absence of VMO tension results in a lateral displacement of the patella and an increased load on the lateral femoral condyle and the lateral patellar facet. This might indicate that, after PDP, the VMO might lose some medial contraction force and thus increase the risk of patella dislocation as a result of decreased medial reaction force. Finally, it could be hypothesized that patella dislocation also impairs afferent nerve fibers in the VMO, leading to a prolonged reflect contraction time and also increasing the risk of redislocation episodes.

In this study we did not perform any repair to the VMO aponeurosis; rather, we only reinserted the MPFL. This might be one reason why MPFL repair had no effect on the redislocation rate in this study. However, the middle part of the MPFL joins with the VMO aponeurosis, and thus a reinsertion of the MPFL ought to restore some of the normal biomechanical direction/force of the muscle.²⁰

Another factor that might influence the outcome after MPFL repair is the difference between acute or delayed repair. In our study we performed a delayed repair (mean, 50 days after injury), which could reduce the chance of optimal anatomic repair to medial structures. However, our method was not an attempt to perform an anatomic repair; rather, we sought to perform suture reinforcement of the scarified MPFL tissue, combined with a reinsertion with anchors at the AT. It could be speculated that an earlier repair could have resulted in a better outcome. However, acute surgery for these patients was not an option in our national health care system. We hypothesized that soft-tissue consolidation (with elongation) before re-

insertion could be advantageous. The consolidated soft tissue could provide a better possibility to avoid further tissue elongation in the ligament and also enable a more precise tensioning of the ligament during surgery. Finally, the suture fixation is stronger in consolidated tissue. Despite all these considerations that could favor delayed MPFL repair, we did not find any benefit of the procedure compared with nonoperative treatment.

The perioperative experience from this study was that the morphology of the MPFL after dislocation of the patella varied in structure from very thin, ill-defined ligaments to relatively solid structures. An MPFL repair with anchors in the bone and sutures in the ligament will never be stronger than the weakest component. Even if the suture is used in a Kessler-like fashion as described by Garth et al.²¹ or as a baseball-stitch suture from the anchors to the VMO junction as in this study, there is a risk of suture loosening. However, in the patients with redislocations, we did not see any suture anchor pullout, so we expect that suture repair provides insufficient mechanical strength for adequate MPFL function.

Although this study was designed to provide an optimal level of evidence as a randomized controlled trial, it has some limitations. Patellofemoral dysplasia is a known predisposing factor for recurrent patella dislocation, and it could be speculated that only including patients with dysplasia could result in a different outcome of the study by only treating patients at a higher risk of redislocation. Time from patella dislocation to surgery varied from days to several months because of referral patients and waiting-list issues that were unavoidable in our public health care system. Finally, the actual redislocation rate in the conservative treatment group was lower than the expected rate, making it more difficult to show a significant difference between the 2 treatment groups. However, the redislocation rates were nearly equal, so equality for this end-point is clearly shown.

CONCLUSIONS

Delayed primary repair of the MPFL by use of an anchor-based reattachment to the AT without VMO repair after primary patella dislocation does not reduce the risk of redislocation nor does it produce any significantly better subjective functional outcome based on the Kujala knee score. Only the specific subjective patella stability score was improved by MPFL repair compared with conservative treatment. Therefore we must reject our hypothesis that surgical MPFL rein-

sersion with our technique provides superior clinical results compared with conservative treatment.

REFERENCES

- Nomura E. Classification of lesions of the medial patellofemoral ligament in patellar dislocation. *Int Orthop* 1999;23:260-263.
- Hautamaa PV, Fithian DC, Kaufman KR, Daniel DM, Pohlmeier AM. Medial soft tissue restraints in lateral patellar instability and repair. *Clin Orthop Relat Res* 1998;174-182.
- Desio SM, Burks RT, Bachus KN. Soft tissue restraints to lateral patellar translation in the human knee. *Am J Sports Med* 1998;26:59-65.
- Sallay PI, Poggi J, Speer KP, Garrett WE. Acute dislocation of the patella. A correlative pathoanatomic study. *Am J Sports Med* 1996;24:52-60.
- Feller JA, Feagin JA Jr, Garrett WE Jr. The medial patellofemoral ligament revisited: An anatomical study. *Knee Surg Sports Traumatol Arthrosc* 1993;1:184-186.
- Koskinen SK, Rantanen JP, Nelimarkka OI, Kujala UM. Effect of Elmslie-Trillat and Roux-Goldthwait procedures on patellofemoral relationships and symptoms in patients with patellar dislocations. *Am J Knee Surg* 1998;11:167-173.
- McManus F, Rang M, Heslin DJ. Acute dislocation of the patella in children. The natural history. *Clin Orthop Relat Res* 1979;88-91.
- Hawkins RJ, Bell RH, Anisette G. Acute patellar dislocations. The natural history. *Am J Sports Med* 1986;14:117-120.
- Maenpaa H, Lehto MU. Patellar dislocation. The long-term results of nonoperative management in 100 patients. *Am J Sports Med* 1997;25:213-217.
- Feller JA, Amis AA, Andrich JT, Arendt EA, Erasmus PJ, Powers CM. Surgical biomechanics of the patellofemoral joint. *Arthroscopy* 2007;23:542-553.
- Barber FA, McGarry JE. Elmslie-Trillat procedure for the treatment of recurrent patellar instability. *Arthroscopy* 2008;24:77-81.
- Christiansen SE, Jacobsen BW, Lund B, Lind M. Reconstruction of the medial patellofemoral ligament with gracilis tendon autograft in transverse patellar drill holes. *Arthroscopy* 2008;24:82-87.
- Ahmad CS, Stein BE, Matuz D, Henry JH. Immediate surgical repair of the medial patellar stabilizers for acute patellar dislocation. A review of eight cases. *Am J Sports Med* 2000;28:804-810.
- Nikku R, Nietosvaara Y, Kallio PE, Aalto K, Michelsson JE. Operative versus closed treatment of primary dislocation of the patella. Similar 2-year results in 125 randomized patients. *Acta Orthop Scand* 1997;68:419-423.
- Mountney J, Senavongse W, Amis AA, Thomas NP. Tensile strength of the medial patellofemoral ligament before and after repair or reconstruction. *J Bone Joint Surg Br* 2005;87:36-40.
- Spritzer CE, Courneya DL, Burk DL Jr, Garrett WE, Strong JA. Medial retinacular complex injury in acute patellar dislocation: MR findings and surgical implications. *AJR Am J Roentgenol* 1997;168:117-122.
- Fithian DC, Paxton EW, Cohen AB. Indications in the treatment of patellar instability. *J Knee Surg* 2004;17:47-56.
- Conlan T, Garth WP Jr, Lemons JE. Evaluation of the medial soft-tissue restraints of the extensor mechanism of the knee. *J Bone Joint Surg Am* 1993;75:682-693.
- Goh JC, Lee PY, Bose K. A cadaver study of the function of the oblique part of vastus medialis. *J Bone Joint Surg Br* 1995;77:225-231.
- Tuxoe JI, Teir M, Winge S, Nielsen PL. The medial patellofemoral ligament: A dissection study. *Knee Surg Sports Traumatol Arthrosc* 2002;10:138-140.
- Garth WP Jr, DiChristina DG, Holt G. Delayed proximal repair and distal realignment after patellar dislocation. *Clin Orthop Relat Res* 2000;132-144.