



## ■ REVIEW ARTICLE

# What is the role of lateral retinacular release?

R. Clifton,  
C. Y. Ng,  
R. W. Nutton

*From the Royal  
Infirmary of  
Edinburgh,  
Edinburgh, Scotland*

**We have reviewed the literature to establish the role of lateral retinacular release in the management of disorders of the extensor apparatus of the knee. The scientific evidence for intervention is explored and reports on outcome are discussed.**

Division of the lateral patellar retinaculum (lateral release) as an open or arthroscopic procedure is commonly performed for disorders of the extensor mechanism of the knee.<sup>1-8</sup> The concept behind lateral release is that imbalance in the extensor mechanism, because of overconstraint by the lateral retinaculum, is the cause of patellofemoral disorders, particularly pain in the anterior knee,<sup>9-12</sup> patellofemoral instability<sup>13-19</sup> and chondromalacia of the articular cartilage of the patella.<sup>20-26</sup> We have examined evidence from published studies on the kinematics of the patellofemoral joint as to how this is affected by lateral release. The clinical effectiveness of lateral release is reviewed and we suggest how it may be applied most effectively in the management of disorders of the patellofemoral joint.

### Anatomy of the knee extensor mechanism

The patellofemoral joint is intrinsically unstable and relies on bony morphology and active and passive soft-tissue forces to maintain stability. The shape of the patella<sup>27</sup> and developmental abnormalities of the femoral trochlea<sup>28</sup> have been shown to affect patellar tracking and stability. Soft-tissue attachments to the patella contribute active stabilising forces through vastus medialis obliquus<sup>29</sup> and passive stabilisers principally through the medial patellofemoral ligament<sup>30</sup> and the attachments of the lateral retinaculum<sup>31,32</sup> (Fig. 1). Imbalance may arise because of weakness in the dynamic stabilisers (vastus medialis obliquus) or overconstraint from the passive stabilisers (lateral retinaculum). The role of the latter is to resist medial displacement of the patella, counteracting the dynamic medialising force generated by the former. These competing forces are influenced by the Q-angle<sup>33</sup> and the morphology of

the patellofemoral joint.<sup>27</sup> Imbalance in this mechanism is usually represented as overconstraint by the lateral retinaculum and weakness in the vastus medialis obliquus which results in maltracking of the patella during flexion of the knee<sup>30,34</sup> and abnormal loading of the patellofemoral joint surfaces. This imbalance may be addressed by strengthening vastus medialis obliquus by appropriately focused rehabilitation, but release of the apparently 'tight' lateral retinaculum has also been proposed.<sup>1</sup>

### Biomechanical effects of lateral release

The effect of lateral release on patellar biomechanics has been examined in several cadaver studies. Ostermeier et al<sup>35</sup> used eight fresh-frozen cadaver specimens to measure patellofemoral contact pressures and kinematics using a pressure-sensitive film and an ultrasound-based movement analysis system. Knees were compared before and after lateral release. They found that patellofemoral contact pressure did not change significantly although the centre of patellofemoral contact pressure was significantly medialised between 60° and 120° of flexion. Studies on patellofemoral kinematics after lateral release showed that the patella moved from a medialised position in flexion to a lateralised position in full knee extension compared with the intact knee. They concluded that lateral release did not stabilise or medialise patellar tracking through the entire range of movement, but it could decrease pressure on the lateral patellar facet in flexion.

Christoforakis et al<sup>36</sup> examined quantitatively the effects of lateral release on the lateral stability of the patella. In seven cadaver specimens they used a materials-testing machine to measure the force required to displace the patella 10 mm laterally while the quadriceps

■ R. Clifton, MSc(Orth Eng),  
FRCS(Trauma & Orth), Locum  
Consultant Orthopaedic  
Surgeon  
Department of Orthopaedics  
Addenbrookes Hospital, Hills  
Road, Cambridge CB2 0QQ, UK.

■ C. Y. Ng, MRCS Ed, Specialist  
Registrar  
■ R. W. Nutton, MD, FRCS,  
Consultant Orthopaedic  
Surgeon  
Department of Orthopaedics  
Royal Infirmary of Edinburgh,  
Little France, 51 Old Dalkeith  
Road, Edinburgh EH16 4SU,  
UK.

Correspondence should be sent  
to Mr R. Clifton; e-mail:  
rupert@doctors.net.uk

©2010 British Editorial Society  
of Bone and Joint Surgery  
doi:10.1302/0301-620X.92B1.  
22909 \$2.00

*J Bone Joint Surg [Br]*  
2010;92-B:1-6.

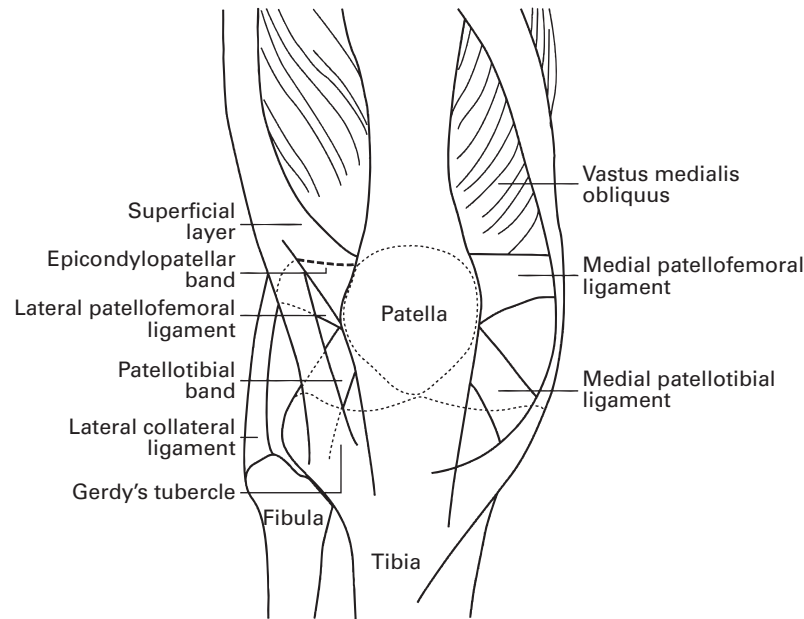


Fig. 1

Diagram showing the extensor mechanism and structures of the lateral retinaculum.

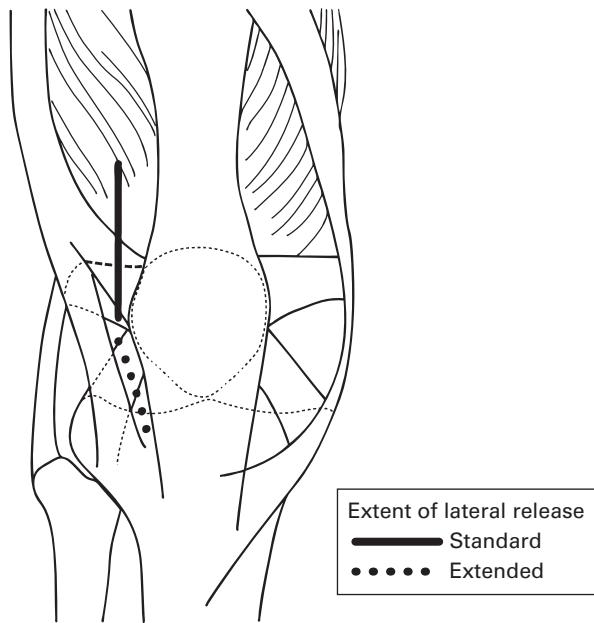


Fig. 2

Diagram showing the extent of the standard and extended lateral retinacular release.

remained under tension. Lateral release significantly reduced the force required and they concluded that it was not appropriate for the treatment of patellar instability. Marumoto, Jordan and Atkins<sup>37</sup> compared different methods of lateral release. They examined release of the

patella from its lateral retinaculum in ten cadaver knees and compared the medial displacement of the patella relative to the femur in two groups. Group A had retinacular release from the inferior third of the tendon of vastus lateralis down to the anterolateral arthroscopic portal. In group B this release extended from the inferior third of the tendon of vastus lateralis to the tibial tubercle (Fig. 2). The extended release (group B) resulted in a significantly greater medial patellar displacement. Since the distal part of vastus lateralis originates from the lateral intermuscular septum and its fibres are orientated to resist medial patellar displacement, these fibres can be divided during a lateral release without transecting the main tendon of vastus lateralis. The method avoids over-release and possible medial instability.<sup>38</sup>

Merican, Kondo and Amis<sup>39</sup> evaluated changes in patellofemoral stability with a progressively more extensive lateral release. They measured the force required to displace the patella 10 mm medially and laterally in nine cadaver knees with and without loading of the tendon of quadriceps and the iliotibial band. The knee was tested intact and after progressive lateral release beginning proximal to the patella extending to the midpoint between the proximal and distal poles of the patella and then distally to Gerdy's tubercle, the site of attachment of the iliotibial tract to the tibia. They found that the midpart of the lateral retinaculum contributed most to the medial stability of the patella, but were unable to say at what point the release would result in over-correction and medial subluxation of the patella.

The relationship between lesions in the articular cartilage and biomechanical factors remains unclear. Wiberg<sup>27</sup>

was unable to confirm a relationship between chondromalacia and the morphology of the patella, although an asymmetrically large lateral facet was associated with maltracking. The most significant factors in the development of lesions of the cartilage appear to be mechanical, resulting from abnormal loading patterns and excessive contact force. Seedholm et al<sup>40</sup> showed that most lesions to the articular cartilage occur in those areas which are in contact during 40° to 80° of flexion, suggesting that excessive joint loading in the mid-range of flexion contributes to the development of these degenerative changes, although they may not necessarily cause symptoms. MacIntyre et al<sup>41</sup> examined three-dimensional patellofemoral joint kinematics using a validated MRI method. The first study group of 20 subjects had patellofemoral pain and clinical signs of patellar malalignment. The second group comprised 20 patients with patellofemoral pain syndrome, but no clinical evidence of patellar malalignment. A control group of 20 volunteers with no history of knee injury or symptoms was recruited from the same military community. There were overlaps in the values for patellar kinematics measured in the subjects with patellofemoral pain, with or without patellar malalignment, and in the control group. The patella shifted medially during the initial 30° to 35° of flexion before shifting laterally by approximately the same amount. In the symptomatic group with malalignment, the patella was positioned more laterally through the full range of knee movement tested, but this was only statistically significant at 19° of knee flexion. Many patients with patellofemoral pain have normal kinematics and although lateral release has been shown to influence joint contact pressures<sup>35</sup> and patellar stability,<sup>39</sup> its effectiveness for patellofemoral pain and instability has not been well established.

### **Lateral release for anterior knee pain**

Lateral release has been used to treat anterior knee pain with reported patient satisfaction ranging from 14% to 100%.<sup>3,7,14,23,42</sup> Meaningful comparison of the results has been hampered by differences in patient selection, methods of evaluation and the length of follow-up. In addition, some studies included patients with both anterior knee pain and patellofemoral instability.<sup>8,15,43-45</sup> Despite the heterogeneity of these reported studies, certain factors appear to be associated with a poorer outcome. Micheli and Stanitski<sup>4</sup> noted that women had a worse prognosis than men and that inadequate realignment of the patella in the trochlear sulcus on post-operative radiographs and severe chondromalacia were associated with poor results. Dzioba<sup>46</sup> similarly highlighted the importance of the reduction of the patella when viewed in a Merchant view (patient supine and knees flexed 45° over end of the table x-ray tube set at 30° angle with floor). Metcalf<sup>13</sup> reported that the proportion of good and excellent results deteriorated with follow-up beyond one year and deterioration was more common in young women who failed to main-

tain their quadriceps strength. Krompinger and Fulkerson<sup>9</sup> reported less satisfactory results when the Q-angle was greater than 20° and Gecha and Torg<sup>11</sup> reported better results when malalignment and hypermobility were absent and found that a positive Sage sign (medial displacement of the patella less than 25% of the patellar width), correlated with better results. Aglietti et al<sup>14</sup> stated that 60% of patients affected by anterior knee pain without grade-III or grade-IV cartilage changes<sup>47</sup> would benefit from a lateral release. More recently, Vaatainen et al<sup>24</sup> performed a prospective, but non-randomised, comparative study of lateral release for anterior knee pain and found that it reduced lateral patellar tilting and lateral patellar displacement, but that the functional capacity of the patients was not improved at four years. In another comparative study, Korkala et al<sup>25</sup> reported results in patients with arthroscopically-diagnosed chondromalacia treated either conservatively or by open lateral release. A lateral release tended to improve patients with grade-II to grade-IV<sup>47</sup> chondromalacia, although this did not reach statistical significance.

The aetiology of patellar pain remains poorly understood. Mori et al<sup>48</sup> performed histological examinations of the resected lateral retinaculum in 35 knees with anterior knee pain. They identified evidence of degenerative neuropathy in 29 specimens and suggested that anterior knee pain may originate in the lateral retinaculum in many patients. If this theory is true a lateral release would denervate this tissue producing relief from the symptoms.

Koskinen et al<sup>26</sup> used MRI in 11 knees with chondromalacia to assess patellar motion pre- and post-lateral release at 0°, 10°, 20° and 30° of flexion. The pre-operative patellar position clearly deviated from normal at 0° to 10° of flexion and lateral release corrected this deviation. Fulkerson and Shea<sup>1</sup> emphasised this concept by recommending that pre-operative CT of the patellofemoral joint be performed to demonstrate a tight lateral retinaculum, causing lateral patellar tilt. Knees showing lateral patellar tilt without subluxation were more likely to benefit from a lateral release in the absence of grade-III or grade-IV changes in the articular cartilage.

In summary, anterior knee pain is almost certainly a multifactorial condition. In those patients with increased lateral facet pressure as demonstrated by the Sage sign and with patellar tilting as seen by CT a lateral release including the deep transverse component of the tendon of vastus lateralis may be effective in correcting lateral patellar tilt. The results are less satisfactory in those patients with established grade-III or grade-IV changes in the articular cartilage and in whom patellar instability rather than lateral retinacular tightness is the principal abnormality.

### **Lateral release for recurrent patellar instability**

Lateral release either in isolation or as part of a more complex stabilisation procedure has been used to treat recurrent patellar instability. The reported proportion of satisfactory results after lateral release alone for patellar instability varies

between 30% and 100%.<sup>14,16,19,49,50</sup> Variations in the reported follow-up make comparison of the literature difficult. Dandy and Griffiths<sup>18</sup> reported on 41 knees which had undergone lateral release for recurrent dislocation after a mean follow-up of four years and found that 90% were classified as 'excellent' or 'good' according to the rating system of Crosby and Insall.<sup>51</sup> After eight years, 33 of the original series were reviewed by Dandy and Desai,<sup>19</sup> who found that the proportion of excellent results had decreased with time from 39% at four years to 30% at eight years. Panni et al<sup>49</sup> also noted a deterioration in the results over time in a group of 50 patients who were followed up for five to 12 years. Satisfaction rates were 70% in patients without instability and 50% in those with instability at follow-up. In other studies, subluxation of the patella in extension, generalised ligamentous laxity,<sup>18,19</sup> damage to the articular cartilage and particularly exposure of bone at the time of lateral release,<sup>49</sup> were identified as poor prognostic factors. Aglietti, Pisaneschi and De Biase<sup>52</sup> showed that lateral release alone for patellar instability led to the current dislocation in 35% of patients and Dainer et al<sup>53</sup> concluded that lateral release as treatment for recurrent patellar dislocation was ineffective.

One group of patients who are reported to respond better to lateral release for instability are adolescents. Gerbino et al<sup>50</sup> found that 92% of patients with a mean age of 15.4 years (SD 2.7) were satisfied or very satisfied at a mean follow-up of 8.5 years, but this may be explained by declining levels of activity with age.

In patellar instability attention must be paid to the exact cause of the instability. An increased tibial tuberosity-trochlear groove distance may require a combined lateral release and transfer of the distal tibial tuberosity. Trochlear dysplasia may require trochleoplasty but a knee with a normal trochlear and tibial tuberosity-trochlear groove distance, but, a weak or absent medial patellofemoral ligament, will benefit from reconstruction of the medial patellofemoral ligament. A more in-depth review on the management of patellar instability has been published by Colvin and West.<sup>54</sup>

### Lateral release for patellofemoral arthritis

Lateral release for isolated patellofemoral arthritis has poor results. Aglietti et al<sup>14</sup> found that only one in six knees with patellofemoral arthritis improved at a mean follow-up of four years after lateral release. More recently, Aderinto and Cobb<sup>55</sup> concluded that lateral release was a poor treatment for patellofemoral arthritis. At a mean follow-up of 31 months they found that only 59% of patients were satisfied or very satisfied with their knee. The only exception to these studies has been that of Alemdaroglu et al<sup>56</sup> who combined lateral release with debridement of the patellofemoral joint by bipolar radiofrequency. The visual analogue scale for pain and the Western Ontario and McMaster Universities osteoarthritis index score decreased significantly in the first three months post-operatively and these improvements were maintained at 24 months.

### Lateral release in total knee replacement

Various authors have investigated the role of lateral release during total knee replacement (TKR). Ritter, Keating and Faris<sup>57</sup> performed one of the largest studies comparing lateral release with no release in 48 patients undergoing simultaneous bilateral TKR. Radiologically, there were no subluxations, dislocations or fractures in either group. Bone scans showed no differences between the two groups and no signs of osteonecrosis of the patella up to 12 years after TKR. Scuderi et al<sup>58</sup> found differently. They performed a prospective, clinical and radionuclide study to determine the effect of lateral release on patellar vascularity in 36 knees. Their results showed a higher incidence of vascular compromise in knees with lateral release (9 of 16, 56.4%) than in those without lateral release (3 of 20, 15.0%). In addition, lateral release has been associated with a higher incidence of vascular compromise to the patella as observed on post-operative technetium bone scans<sup>59</sup> and a reduction in the viability of the stem of the lateral wound-edge as determined by measurement of the transcutaneous oxygen tension.<sup>60</sup>

Efforts have been made to reduce the need for lateral release to correct patellar maltracking in knee replacement. Laskin<sup>61</sup> and Lombardi et al<sup>62</sup> both examined the effect of tourniquet release before performing lateral release and found that it resulted in a reduced incidence of lateral release of between 6%<sup>61</sup> and 22%.<sup>62</sup> Archibeck et al<sup>63</sup> and Weber et al<sup>64</sup> recommended that using the 'rule of no thumb' test in which the knee is flexed and extended before closing the medial retinaculum without support from the thumb to hold the patella in the trochlear groove, reduced the requirement for lateral release. Sodha et al<sup>65</sup> pointed to the importance of avoiding internal rotation of the femoral component to reduce the necessity for lateral release.

### Complications of lateral release

Lateral release can result in serious complications including haemarthrosis, reflex sympathetic dystrophy and medial subluxation of the patella. The incidence of haemarthrosis has been reported to be between 1% and 42%,<sup>6,14,66</sup> but may be higher after arthroscopic techniques when the superolateral geniculate artery has not been identified and coagulated. Arthroscopic diathermy has allowed coagulation of bleeding vessels under direct vision to reduce this complication.<sup>17</sup> Medial subluxation of the patella after excessive lateral release has been described. Hughston et al<sup>67</sup> studied 65 knees which required surgical treatment to correct medial subluxation of the patella, of which 58 had previously undergone a lateral release. They recommended that the knee should be flexed and extended several times to confirm improved tracking of the patella after lateral release. Reflex sympathetic dystrophy can also be problematic after lateral release and early recognition is essential to minimise long-term sequelae.<sup>68</sup>

Lateral retinacular release performed in isolation for patellofemoral disorders remains a controversial topic. A lack of well-designed studies with clearly defined inclusion

criteria, standardised methods of assessment and adequate follow-up hinders an informed opinion about the effectiveness of this procedure. It is important to appreciate what will be achieved by release of the lateral retinaculum. For example, in patellar instability it is unrealistic to expect a release of the lateral retinaculum to correct patellar maltracking and instability if there is also trochlear dysplasia, deficiency of the medial patellofemoral ligament, abnormal limb alignment or tibial torsion. Similarly, if anterior knee pain is not associated with an abnormally tight lateral retinaculum a lateral release may produce a temporary improvement by denervating the lateral retinaculum, but the longer term outcome may be disappointing.

Our review has not provided clearly-defined indications for lateral release in all cases, but it is evident that anterior knee pain with clinical signs of lateral retinacular tethering (the Sage sign), confirmed by evidence of patellar tilting on CT is more likely to produce satisfactory results. In patellar instability, several factors contribute to the condition including hypermobility, limb alignment, and trochlear dysplasia, and these must be addressed before formulating an appropriate plan of management. In very few cases an isolated lateral release will be effective in correcting instability. Similarly, at total knee replacement, careful assessment of the positioning of the femoral component and soft-tissue balancing can minimise the requirement for lateral release. In patellofemoral osteoarthritis, the results of lateral release have been disappointing and it should not be used in this condition.

Lateral release is not without potential morbidity and should not be used indiscriminately for patellofemoral disorders.

No benefits in any form have been received or will be received from a commercial party related directly or indirectly to the subject of this article.

## References

- Fulkerson JP, Shea KP. Disorders of patellofemoral alignment. *J Bone Joint Surg [Am]* 1990;72-A:1424-9.
- Ficat P, Hungerford DS. *Disorders of the patellofemoral joint*. Baltimore: Williams & Wilkins, 1977.
- Larson RL, Cabaud HE, Slocum DB, et al. The patellar compression syndrome: surgical treatment by lateral retinacular release. *Clin Orthop* 1978;34:158-67.
- Micheli LJ, Stanitski CL. Lateral patellar retinacular release. *Am J Sports Med* 1981;9:330-6.
- Grana WA, Hinkley B, Hollingsworth S. Arthroscopic evaluation and treatment of patellar malalignment. *Clin Orthop* 1984;186:122-8.
- Schonholtz GJ, Zahn MG, Magee CM. Lateral retinacular release of the patella. *Arthroscopy* 1987;3:269-72.
- Fabbiaciani C, Panni AS, Delcogliano A. Role of arthroscopic lateral release in the treatment of patellofemoral disorders. *Arthroscopy* 1992;8:531-6.
- Bigos SJ, McBride GG. The isolated lateral retinacular release in the treatment of patellofemoral disorders. *Clin Orthop* 1984;186:75-80.
- Krompinger WJ, Fulkerson JP. Lateral retinacular release for intractable lateral retinacular pain. *Clin Orthop* 1983;179:191-3.
- Bray RC, Roth JH, Jacobsen RP. Arthroscopic lateral release for anterior knee pain: study comparing patients who are claiming worker's compensation with those who are not. *Arthroscopy* 1987;3:237-47.
- Gecha SR, Torg JS. Clinical prognosticators for the efficacy of retinacular release surgery to treat patellofemoral pain. *Clin Orthop* 1990;253:203-8.
- Jackson RW, Kunkel SS, Taylor GJ. Lateral retinacular release for patellofemoral pain in the older patient. *Arthroscopy* 1991;7:283-6.
- Metcalf RW. An arthroscopic method for lateral release of subluxating or dislocating patella. *Clin Orthop* 1982;167:9-18.
- Aglietti P, Pisaneschi A, Buzzi R, Gaudenzi A, Allegra M. Arthroscopic lateral release for patellar pain or instability. *Arthroscopy* 1989;5:176-83.
- Henry JH, Goletz TH, Williamson B. Lateral retinacular release in patellofemoral subluxation: indications, results, and comparison to open patellofemoral reconstruction. *Am J Sports Med* 1986;14:121-9.
- Chen SC, Ramanathan EB. The treatment of patellar instability by lateral release. *J Bone Joint Surg [Br]* 1984;66-B:344-8.
- Sherman OH, Fox JM, Sperling H, et al. Patellar instability: treatment by arthroscopic electro-surgical lateral release. *Arthroscopy* 1987;3:152-60.
- Dandy DJ, Griffiths D. Lateral release for recurrent dislocation of the patella. *J Bone Joint Surg [Br]* 1989;71-B:121-5.
- Dandy DJ, Desai SS. The results of arthroscopic lateral release of the extensor mechanism for recurrent dislocation of the patella after 8 years. *Arthroscopy* 1994;10:540-5.
- Harwin SF, Stern RE. Subcutaneous lateral retinacular release for chondromalacia patellae: a preliminary report. *Clin Orthop* 1981;156:207-10.
- Osborne AH, Fulford PC. Lateral release for chondromalacia patellae. *J Bone Joint Surg [Br]* 1982;64-B:202-5.
- Ogilvie-Harris DJ, Jackson RW. The arthroscopic treatment of chondromalacia patellae. *J Bone Joint Surg [Br]* 1984;66-B:660-5.
- Christensen F, Søballe K, Snerum L. Treatment of chondromalacia patellae by lateral retinacular release of the patella. *Clin Orthop* 1988;234:145-7.
- Vaatainen U, Kiviranta I, Jaroma H, Airaksinen O. Lateral release in chondromalacia patellae using clinical, radiologic, electromyographic, and muscle force testing evaluation. *Arch Phys Med Rehabil* 1994;75:1127-31.
- Korkala OL, Isotalo TM, Lavonius MI, Niskanen RO. Outcome and clinical signs of arthroscopically graded patellar chondromalacia with or without lateral release. *Ann Chir Gynaecol* 1995;84:276-9.
- Koskinen SK, Hurme M, Kujala UM, Korman M. Effect of lateral release on patellar motion in chondromalacia: an MRI study of 11 knees. *Acta Orthop Scand* 1990;61:311-12.
- Wiberg G. Roentgenographic and anatomic studies on the patellofemoral joint: with special reference to chondromalacia patellae. *Acta Orthop* 1941;12:319-410.
- Fulkerson JP, Hungerford DS. Normal anatomy. In: *Disorders of the patellofemoral joint*. Second ed. Baltimore: Williams & Wilkins, 1990:1.
- Conlan T, Garth WP Jr, Lemons JE. Evaluation of the medial soft-tissue restraints of the extensor mechanism of the knee. *J Bone Joint Surg [Am]* 1993;75-A:682-93.
- Koskinen SK, Kujala UM. Patellofemoral relationships and distal insertion of the vastus medialis muscle: a magnetic resonance imaging study in non symptomatic subjects and in patients with patellar dislocation. *Arthroscopy* 1992;8:465-8.
- Fulkerson JP, Gossling HR. Anatomy of the knee joint lateral retinaculum. *Clin Orthop* 1980;153:183-8.
- Merican AM, Amis AA. Anatomy of the lateral retinaculum of the knee. *J Bone Joint Surg [Br]* 2008;90-B:527-34.
- Fulkerson JP, Hungerford DS. Biomechanics of the patellofemoral joint. In: *Disorders of the patellofemoral joint*. Second ed. Baltimore: Williams & Wilkins, 1990:25.
- Lieb FJ, Perry J. Quadriceps function: an anatomical and mechanical study using amputated limbs. *J Bone Joint Surg [Am]* 1968;50-A:1535-48.
- Ostermeier S, Holst M, Hurschler C, Windhagen H, Stukenborg-Colsman C. Dynamic measurement of patellofemoral kinematics and contact pressure after lateral retinacular release: an in vitro study. *Knee Surg Sports Traumatol Arthrosc* 2007;15:547-54.
- Christoforakis J, Bull AM, Strachan RK, et al. Effects of lateral retinacular release on the lateral stability of the patella. *Knee Surg Sports Traumatol Arthrosc* 2006;14:273-7.
- Marumoto JM, Jordan C, Akins R. A biomechanical comparison of lateral retinacular releases. *Am J Sports Med* 1995;23:151-5.
- Hallisey MJ, Doherty N, Bennett WF, Fulkerson JP. Anatomy of the junction of the vastus lateralis tendon and the patella. *J Bone Joint Surg [Am]* 1987;69-A:545-9.
- Merican AM, Kondo E, Amis AA. The effect on patellofemoral joint stability of selective cutting of lateral retinacular and capsular structures. *J Biomech* 2009;42:291-6.
- Seedholm BB, Takeda T, Tsubuku M, Wright V. Mechanical factors and patellofemoral osteoarthritis. *Ann Rheum Dis* 1979;38:307-16.
- MacIntyre NJ, Hill NA, Fellows RA, Ellis RE, Wilson DR. Patellofemoral joint kinematics in individuals with and without patellofemoral pain syndrome. *J Bone Joint Surg [Am]* 2006;88-A:2596-605.
- Johnson RP. Lateral facet syndrome of the patella: lateral restraint analysis and use of lateral resection. *Clin Orthop* 1989;238:148-58.
- McGinty JB. Arthroscopy of the knee. In: Insall JN, ed. *Surgery of the knee*. New York: Churchill Livingstone, 1984:111.
- McGinty JB, McCarthy JC. Endoscopic lateral retinacular release: a preliminary report. *Clin Orthop* 1981;158:120-5.
- Merchant AC, Mercer RL. Lateral release of the patella: a preliminary report. *Clin Orthop* 1974;103:40-5.

46. **Dzioba RB.** Diagnostic arthroscopy and longitudinal open lateral release: a four year follow-up study to determine predictors of surgical outcome. *Am J Sports Med* 1990;18:343-8.
47. **Outerbridge RE.** The etiology of chondromalacia patellae. *J Bone Joint Surg [Br]* 1961;43-B:752-7.
48. **Mori Y, Fujimoto A, Okumo H, Kuroki Y.** Lateral retinaculum release in adolescent patellofemoral disorders: its relationship to peripheral nerve injury in the lateral retinaculum. *Bull Hosp Jt Dis Orthop Inst* 1991;51:218-29.
49. **Panni AS, Tartarone M, Patricola A, Paxton EW, Fithian DC.** Long-term results of lateral retinacular release. *Arthroscopy* 2005;21:526-31.
50. **Gerbino PG, Zurakowski D, Soto R, et al.** Long-term functional outcome after lateral patellar retinacular release in adolescents: an observational cohort study with minimum 5-year follow-up. *J Pediatr Orthop* 2008;28:118-23.
51. **Crosby EB, Insall J.** Recurrent dislocation of the patella: relation of treatment to osteoarthritis. *J Bone Joint Surg [Am]* 1976;58-A:9-13.
52. **Aglietti P, Pisaneschi A, De Biase P.** Recurrent dislocation of patella: three kinds of surgical treatment. *Ital J Orthop Traumatol* 1992;18:25-36.
53. **Dainer RD, Barrack RL, Buckley SL, Alexander AH.** Arthroscopic treatment of acute patellar dislocations. *Arthroscopy* 1988;4:267-71.
54. **Colvin AC, West RV.** Patellar instability. *J Bone Joint Surg [Am]* 2008;90-A:2751-62.
55. **Aderinto J, Cobb AG.** Lateral release for patellofemoral arthritis. *Arthroscopy* 2002;18:399-403.
56. **Alemdaroglu KB, Cimen O, Aydogan NH, Atilhan D, Iltar S.** Early results of arthroscopic lateral retinacular release in patellofemoral osteoarthritis. *Knee* 2008;15:451-5.
57. **Ritter MA, Keating EM, Faris PM.** Clinical, roentgenographic, and scintigraphic results after interruption of the superior lateral genicular artery during total knee arthroplasty. *Clin Orthop* 1989;248:145-51.
58. **Scuderi G, Scharf SC, Meltzer LP, Scott WN.** The relationship of lateral releases to patella viability in total knee arthroplasty. *J Arthroplasty* 1987;2:209-14.
59. **McMahon MS, Scuderi GR, Glashow JL, et al.** Scintigraphic determination of patellar viability after excision of infrapatellar fat pad and/or lateral retinacular release in total knee arthroplasty. *Clin Orthop* 1990;260:10-16.
60. **Johnson DP, Eastwood DM.** Lateral patellar release in knee arthroplasty: effect on wound healing. *J Arthroplasty* 1992;7(Suppl):427-31.
61. **Laskin RS.** Lateral release rates after total knee arthroplasty. *Clin Orthop* 2001;392:88-93.
62. **Lombardi AV Jr, Berend KR, Mallory TH, Dodds KL, Adams JB.** The relationship of lateral release and tourniquet deflation in total knee arthroplasty. *J Knee Surg* 2003;16:209-14.
63. **Archibeck MJ, Camarata D, Trauger J, Allman J, White RE Jr.** Indications for lateral retinacular release in total knee replacement. *Clin Orthop* 2003;414:157-61.
64. **Weber AB, Worland RL, Jessup DE, Van Bowen J, Keenan J.** The consequences of lateral release in total knee replacement: a review of over 1000 knees with follow up between 5 and 11 years. *Knee* 2003;10:187-91.
65. **Sodha S, Kim J, McGuire KJ, Lonner JH, Lotke PA.** Lateral retinacular release as a function of femoral component rotation in total knee arthroplasty. *J Arthroplasty* 2004;19:459-63.
66. **Small NC.** Complications in arthroscopic surgery performed by experienced arthroscopists. *Arthroscopy* 1988;4:215-21.
67. **Hughston JC, Flandry F, Brinker MR, Terry GC, Mills JC 3rd.** Surgical correction of medial subluxation of the patella. *Am J Sports Med* 1996;24:486-91.
68. **O'Brien SJ, Ngeow J, Gibney MA, Warren RF, Fealy S.** Reflect sympathetic dystrophy of the knee: causes, diagnosis, and treatment. *Am J Sports Med* 1995;23:655-9.