

## Technical Note With Video Illustration

# Anteromedial Portal Technique for the Anterior Cruciate Ligament Femoral Socket: Pitfalls and Solutions

James H. Lubowitz, M.D.

---

**Abstract:** Creating the anterior cruciate ligament (ACL) femoral socket using the anteromedial (AM) portal technique has advantages. Furthermore, the technique is ideal for anatomic double-bundle (particularly posterolateral bundle) and all-inside ACL techniques. However, although the AM portal technique has advantages, the learning curve is steep when making the transition from familiar, transtibial reaming to the AM portal technique for ACL femoral tunnel creation. Complications and challenges are many when learning the AM portal technique. The purpose of this technical note is to describe tips and pearls for surgeons contemplating the transition to the AM portal technique for the ACL femoral socket. **Key Words:** Anterior cruciate ligament—Anteromedial portal technique—Transportal Guide—All inside—Retroconstruction—Double bundle.

---

Creating the anterior cruciate ligament (ACL) femoral socket using the anteromedial (AM) portal technique has advantages (Table 1). Furthermore, the technique is ideal for anatomic double-bundle (particularly posterolateral bundle) and all-inside ACL techniques. Originally described by Bottoni et al.,<sup>1,2</sup> the technique was well characterized by Harner et al.<sup>3</sup> in *Arthroscopy* in 2008. A testament to the advantages of this previously obscure technique is found in *Arthroscopy* journal citations. In the last 3 years, we have identified 4 references to the AM portal tech-

nique for ACL femoral tunnel creation in 2006,<sup>3-7</sup> 6 in 2007,<sup>4-13</sup> and 17 in 2008.<sup>14-30</sup>

However, although the AM portal technique has advantages, the learning curve is steep when making the transition from familiar, transtibial reaming to the AM portal technique for ACL femoral tunnel creation.

Complications and challenges are many when learning the AM portal technique and include (1) very short sockets (or accidental, inadequate socket length resulting in bicortical reaming); (2) socket blowout along the back wall of the lateral femoral intercondylar notch; (3) distal and/or inferior exit of the Beath pin from the lateral thigh (approaching the dangerous region of the peroneal nerve); (4) difficulty seating the femoral endoscopic aimer because of impingement between the instrument and the lateral wall of the intercondylar notch; (5) inability to maintain the position of a properly seated aimer when the knee is brought into the requisite, hyperflexion position; (6) difficulty bringing the acorn reamer over the Beath pin and through the AM portal with the knee in hyperflexion, because hyperflexion causes the portal to tighten; (7) difficulty avoiding iatrogenic damage to the cartilage of the medial femoral condyle as the acorn reamer is advanced over the Beath pin in the hyperflexed knee; (8) difficulty passing the reamer

---

From the Taos Orthopaedic Institute Research Foundation, Taos, New Mexico, U.S.A.

The author has a consulting relationship with Arthrex, Naples, Florida, related to the topic of this article.

Address correspondence and reprints requests to James H. Lubowitz, M.D., Taos Orthopaedic Institute Research Foundation, 1219-A Gusdorf Rd, Taos, NM 87571, U.S.A. E-mail: [jlubowitz@kitcarson.net](mailto:jlubowitz@kitcarson.net)

© 2009 by the Arthroscopy Association of North America  
0749-8063/09/2501-8566\$36.00/0  
doi:10.1016/j.arthro.2008.10.012

Note: To access the supplementary video accompanying this report, visit the January issue of *Arthroscopy* at [www.arthroscopyjournal.org](http://www.arthroscopyjournal.org).

**TABLE 1.** *Advantages of AM Portal Technique for ACL Femoral Socket Creation*


---

Socket placement unconstrained as compared with transtibial portal placement
Essential for all-inside ACL retroconstruction using tibial sockets without full tunnels
Essential for anatomic placement of posterolateral ACL femoral socket during double-bundle ACL reconstruction and usually required for anatomic AM femoral socket during double-bundle reconstruction
For femoral cannulated interference screw fixation option, ensures parallel socket and screw angle (no divergence) because reaming and screwing are via same (AM) portal
Helpful in revision situations where prior high, anterior, misplaced femoral sockets may be avoided because pre-existing transtibial femoral sockets are approached at a different reaming angle

---

over the Beath pin because of a bend in the pin when the knee slips out of hyperflexion; (9) difficulty visualizing the reamer because of ingress of the fat pad, which also occurs when the acorn reamer is advanced over the pin in hyperflexion; (10) difficulty maintaining the position of the arthroscope (generally held by an assistant) in the hyperflexion position; (11) difficulty visualizing the depth markings on the acorn reamer despite proper arthroscope positioning during socket creation, because of the combination of reaming debris and poor flow of arthroscopic fluid, which occurs in hyperflexion; and (12) difficulty with graft or fixation device passage or placement (Table 2). In summary, the learning curve when making the transition from the transtibial, femoral reaming technique to AM portal reaming of the femoral ACL socket is fraught with difficulties and can be frustrating.

The purpose of this technical note is to describe tips and pearls for surgeons contemplating the transition to the AM portal technique for the ACL femoral socket.

### GENERAL PRINCIPLES

First, some surgeons recommend creating an accessory AM portal for viewing the femoral footprint. Although this is not required, it is highly recommended that the AM portal used for reaming the femur be carefully placed. The portal should be as inferior (close to the tibia) as possible, with the caveat that direct visualization with a spinal needle is recommended to avoid placing the portal too inferior, which could damage the anterior horn of the medial meniscus. In addition, the portal should be balanced so as to be as medial as possible for more perpendicular ream-

ing of the lateral wall of the intercondylar notch, yet not so medial that the Beath pin or reamer will damage the cartilage of the medial femoral condyle. Again, direct visualization by use of a spinal needle is helpful.

Next, surgeons should note that the “o’clock” position is relative to knee flexion angle and commonly refers to a knee flexion angle of 90°. However, knee hyperflexion of far greater than 90°—generally maximal hyperflexion—is required when reaming the femoral socket through the AM portal to avoid femoral fracture, back wall blowout, short tunnels, or neurovascular injury. As stated previously, it is often difficult to position the endoscopic aimer with the knee in hyperflexion, and it also may be difficult to bring the reamer over the Beath pin in the hyperflexed position. Thus, as will be described, the aimer, pin, and reamer must be brought into the joint with the knee at 90°; then, the knee is hyperflexed after the pin and reamer are in position. A key pearl is that the Beath pin and reamer may be brought into the joint as a composite, or “couple,”<sup>31</sup> allowing the reamer flutes to be placed around and beyond the medial femoral cartilage. This composite at 90° technique minimizes the challenges and risks that occur when a surgeon attempts to place the reamer over the Beath pin with the Beath pin

**TABLE 2.** *Challenges and Risks of AM Portal Technique for ACL Femoral Socket Creation*


---

Short or bicortical sockets
Socket blowout along back wall of lateral femoral intercondylar notch
Distal and/or inferior exit of Beath pin from lateral thigh endangers peroneal neurovascular structures
Difficulty seating a femoral endoscopic aimer (designed for transtibial technique) because of impingement between instrument and lateral wall of intercondylar notch
Inability to maintain position of properly seated aimer in knee hyperflexion position
Difficulty bringing acorn reamer over Beath pin and through AM portal in knee hyperflexion position because of portal tightening in hyperflexion
Difficulty avoiding iatrogenic damage to cartilage of medial femoral condyle as acorn reamer is advanced over Beath pin in hyperflexion
Difficulty passing reamer over Beath pin because of a bend in pin when knee inadvertently slips out of hyperflexion
Difficulty visualizing reamer because of ingress of fat pad when acorn reamer is advanced over Beath pin in hyperflexion
Difficulty with arthroscopic viewing position in hyperflexion
Difficulty visualizing depth markings on acorn reamer because of reaming debris plus poor flow or difficult viewing position in hyperflexion
Difficulty with graft or fixation device passage or placement

---



**FIGURE 1.** The Transportal Guide is a femoral, endoscopic aimer designed for the AM portal technique for ACL femoral socket creation. A 30° angled offset tip (arrow) minimizes impingement of the body of the aimer against the lateral wall of the intercondylar notch, which occurs when a standard aimer is used via the AM portal. Because the tip is angled, the guide must be fully seated against bone to ensure accuracy to 1 mm increment reproduction of back wall thickness. The angled offset tip also allows a controlled, anterior trajectory of the guide pin or divergence of sockets for double-bundle ACL reconstruction. A final modification is a longer offset tip, required to stabilize the guide over the back wall of the notch if used in a position of extreme knee hyperflexion.

already drilled (transfemoral) and with the knee in hyperflexion (Table 2).

In summary, (1) use a low medial portal, but not too medial; (2) mark the centrum of the femoral tunnel with the knee at 90° flexion; (3) position the “composite” (Beath pin within reamer) at 90° flexion; and (4) hyperflex, pin, and ream.

## TECHNIQUE

### Preserve Back Wall

Conservative selection of the appropriate increment of aimer offset is essential for avoiding a thin back wall. Back wall blowout is a risk because, in extreme knee hyperflexion (required to avoid neurovascular injury and ensure proper tunnel length), the socket may be parallel to the true back wall of the intercondylar notch. Thus a guide increment ensuring a substantial back wall (2 to 3 mm) should be considered. For example, for a 9-mm-diameter reamer, cautiously select a 7-mm-offset Transportal Guide (TPG) (Arthrex, Naples, FL) to ensure a 2.5-mm back wall ( $7 \text{ mm offset} - [9/2] = 2.5 \text{ mm back wall}$ ). In addition to avoiding back wall blowout, surgeons seeking a more “anatomic” single-bundle ACL femoral footprint may find that a thicker back wall allows them to better position the socket between the AM and posterolateral bundle footprints.

### Mark Centrum of Femoral Socket

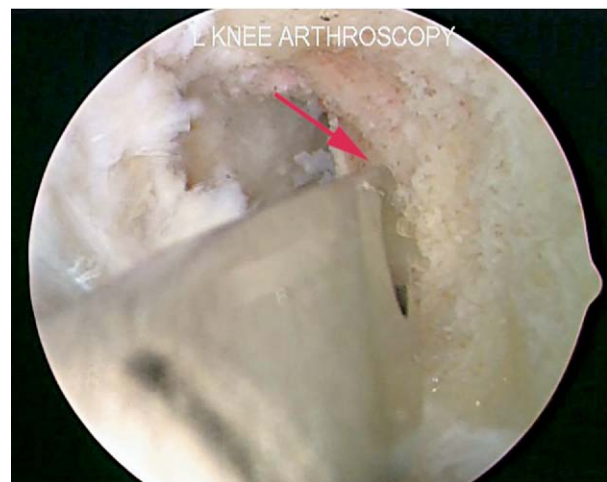Mark the centrum of the planned femoral socket before the knee is hyperflexed. This allows familiar 90° knee flexion position visualization of the true back wall of the notch, o’clock position. This also allows inspection and review of a precise position before

reaming, which—in the opinion of the author—justifies an extra surgical step.

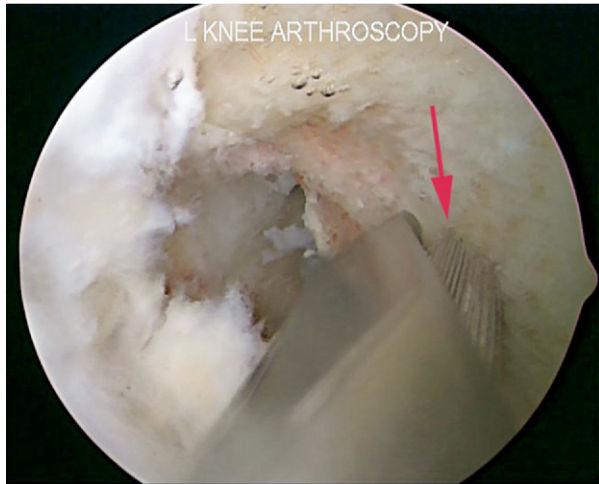Standard, femoral endoscopic aimers have been designed for the transtibial technique. A Transportal ACL Femoral Guide or TPG aimer (Arthrex) is designed to facilitate the AM portal technique for the ACL femoral socket (Fig 1). In the familiar 90° knee flexion position, the TPG is brought through the AM portal and seated at the 10-o’clock position for a right knee or 2-o’clock position for a left knee (Fig 2). A 2.4-mm drill-tipped guide pin, or Beath pin, is brought through the TPG and impacted into the lateral wall of the notch at the centrum of the femoral socket to a depth of 3-5 mm by use of a mallet (Fig 3). The pin is then removed with a Kocher clamp, the position of the mark is inspected, and precise placement of the mark is confirmed from 1 or more portals (Video 1 [online only, available at [www.arthroscopyjournal.org](http://www.arthroscopyjournal.org)], Fig 4).

### Place Composite Reamer Preloaded With Beath Pin

Once the surgeon is satisfied with precise placement of the mark, the appropriate diameter acorn reamer is loaded on a Jacobs chuck, but not yet loaded on a power reamer. Rather, a Beath pin is then preloaded, within the reamer. Next, the composite (reamer preloaded with Beath pin) is placed via the AM portal in the familiar 90° flexion position. At 90° (as opposed to hyperflexion), the portal is not too tight, and fat pad ingress can be avoided.

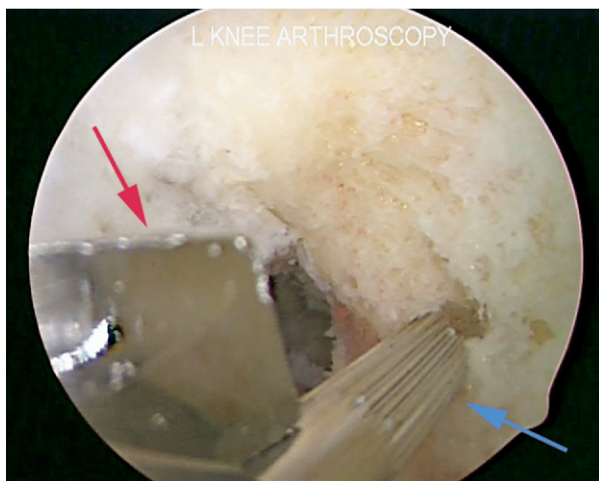


**FIGURE 2.** Arthroscopic anterolateral portal view of left (L) knee showing complete seating of TPG at 2-o’clock position on lateral wall of femoral intercondylar notch via AM arthroscopic portal. The arrow marks the angled offset tip.

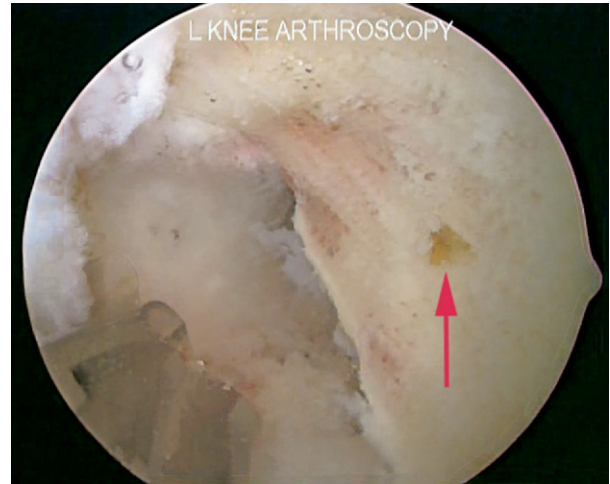

**FIGURE 3.** Arthroscopic anterolateral portal view of left (L) knee showing Beath pin (arrow) brought through TPG (at 2-o'clock position on lateral wall of femoral intercondylar notch via AM arthroscopic portal) and impacted into lateral wall of notch to mark centrum of ACL femoral socket.

In addition, at 90°, it is simple to slip the flutes of the reamer around and past the cartilage of the medial femoral condyle under direct arthroscopic visualization in an unconstrained manner, as well as



**FIGURE 5.** Arthroscopic anterolateral portal view of left (L) knee showing “composite” acorn reamer (red arrow) preloaded with Beath pin (blue arrow) and placed via AM arthroscopic portal at previously marked centrum of ACL femoral socket on lateral wall of femoral intercondylar notch at 2-o'clock position. With the knee at the familiar 90° flexion position, the flutes of the unconstrained (Beath pin not yet seated) reamer may be placed around and past the medial femoral condylar cartilage, avoiding iatrogenic cartilage damage, which may occur when placing the reamer over a seated Beath pin (reamer constrained) or which may occur when placing the reamer after knee hyperflexion.



**FIGURE 4.** Arthroscopic anterolateral portal view of left (L) knee showing marked centrum (arrow) of ACL femoral socket on lateral wall of femoral intercondylar notch at 2-o'clock position.

to avoid iatrogenic cartilage damage, because the Beath pin has not yet been drilled into a constrained (transfemoral) position (Fig 5).

#### Use Reamer as Guide Pin Sleeve

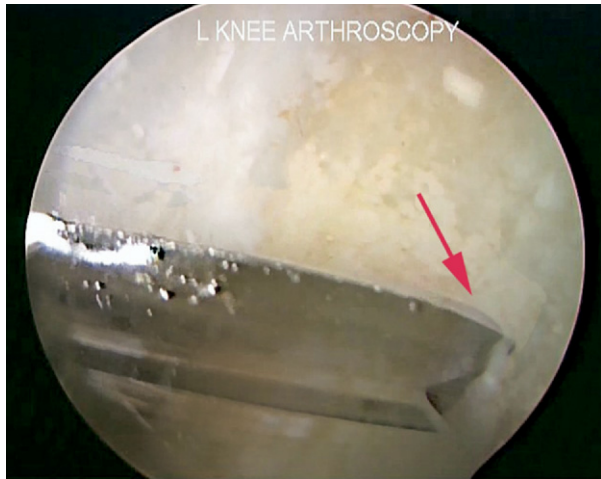
As above, before the Beath pin guides the cannulated reamer, the reamer serves as a guide pin sleeve for the Beath pin.

With the knee remaining at the comfortable and familiar 90° flexion position, the reamer is used as a “Beath pin sleeve,” and the Beath pin is slid through the reamer until the point of the Beath pin is seen to be accurately seated at the marked centrum (Fig 5). Critically, once the pin is seated, the operating surgeon must maintain pressure to ensure that the tip of the Beath pin does not slip from the anatomic position. Now, before reaming, the reamer is seated on bone; the reamer will continue to serve as the Beath pin sleeve. Lastly, the knee is hyperflexed.

#### Knee Hyperflexion and Camera Position

A pearl learned by trial and error is that the arthroscopic camera should be positioned superior to the pin-reamer composite, looking down (Fig 6); this position and view are relatively easy for an assistant to maintain both during the hyperflexion maneuver and in the hyperflexion position.

Once positioned, the assistant must maintain both camera position plus knee hyperflexion during pinning and reaming. Meticulous composite preparation as described previously makes this step simple and re-



**FIGURE 6.** Arthroscopic anterolateral portal view of left (L) knee showing "hyperflexion view." With the knee in extreme hyperflexion, the camera is positioned superiorly in the notch, allowing the arthroscopic surgeon to look down at the fluted head of an acorn reamer placed on the lateral wall of the femoral intercondylar notch at the 2-o'clock position via the AM arthroscopic portal (arrow).

producibile. Lastly, the assistant must be reminded that knee position must be rigidly maintained to avoid bending the Beath pin.

### Drilling Angle

The Beath pin drilling angle determines the angle of the femoral socket. This is important to achieve adequate socket length, as well as to ensure that the pin avoids neurovascular structures.

After the previously mentioned steps, the pin, acorn reamer, camera, and knee should be in the proper position. A drill drives the Beath pin through the femur and out the anterolateral thigh.

A key advantage of the composite is that the reamer, acting as a Beath pin guide sleeve, may be aggressively levered down against the anterior horn of the medial meniscus via the low AM portal. This ensures more superiorly angled egress of the Beath pin out of the anterolateral thigh. As stated previously, this achieves dual goals of steering away from the peroneal nerve and creating a longer socket length. Next, because the reamer is already in position (composite), the drill may be removed from the Beath pin and a power reamer may be chucked to the acorn reamer without additional steps or fiddle-factor. Finally, the ACL femoral socket is reamed through the AM portal.

### Determining Socket Depth

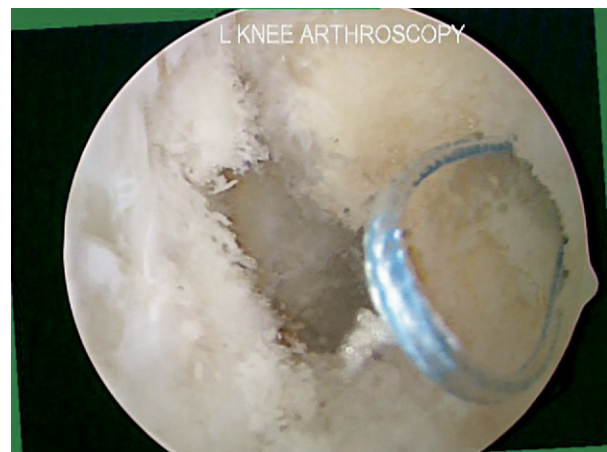Even with perfect position of the arthroscope, difficulty visualizing and reading the 5-mm laser-marked depth markings on the acorn reamer may occur because of the combination of reaming debris and poor flow of arthroscopic fluid, which occurs in hyperflexion. A pearl is to read the laser marks by use of direct visualization of the marks as they pass the AM portal at the skin. This is reliable when the arthroscopic view is obscured.

### Place a Femoral Graft-Passing Suture

The free ends of a suture loop are loaded on the Beath pin, which is advanced out of the anterolateral thigh. The femoral graft-passing suture loop is left in the femoral socket for later retrieval and graft passage (Fig 7). Knee extension may change the position of the graft-passing suture loop, so a pearl is that a surgeon should maintain an adequately long loop as the knee is returned to the 90° position. Alternatively, the loop may be secured outside the portal with a hemostat until the tibia is prepared and the surgeon is ready to retrieve the femoral graft-passing suture loop and pass the graft.

### Graft Passage and Fixation

Because the socket is drilled in hyperflexion, hyperflexion thus aids passage of the graft and/or suspensory fixation buttons. For femoral interference screw fixation, hyperflexion guarantees absolutely



**FIGURE 7.** Arthroscopic anterolateral portal view of left (L) knee showing femoral graft-passing suture loop (blue) positioned in ACL femoral socket for later retrieval and graft passage. The socket was created on the lateral wall of the femoral intercondylar notch at the 2-o'clock position via the AM arthroscopic portal.

parallel screw placement, an advantage of the AM portal reaming technique when compared with transtibial reaming plus AM portal screwing.

### CONTRAINDICATIONS

Because knee hyperflexion is required for this technique, a relative contraindication to this technique is morbid obesity because the patient's body habitus may preclude deep knee flexion.

### CONCLUSIONS

The AM arthroscopic portal technique for creating the ACL femoral socket has many advantages. In contrast to transtibial drilling, the AM portal technique allows unconstrained femoral socket positioning, which is essential for surgeons making a transition to all-inside retroconstruction or double-bundle reconstruction.

The learning curve for the AM portal technique may be steep, but marking the centrum of the tunnel using a TPG aimer while the knee is in the familiar 90° flexion position will insure anatomic tunnel placement. In addition, placing a Beath pin within reamer composite while the knee is in the familiar 90° flexion position, before subsequent knee hyperflexion, will aid surgeons making the transition to the AM portal technique.

### REFERENCES

1. Bottoni CR, Rooney CR, Harprist JK, Kan DA. Ensuring accurate femoral guide pin placement in anterior cruciate ligament reconstruction. *Am J Orthop* 1998;28:764-766.
2. Bottoni CR. Anterior cruciate ligament femoral tunnel creation by use of anteromedial portal. *Arthroscopy* 2008;24:1319 (letter).
3. Harner CD, Honkamp NJ, Ranawat AS. Anteromedial portal technique for creating the anterior cruciate ligament femoral tunnel. *Arthroscopy* 2008;24:113-115.
4. Kim S-J, Jung K-A, Song D-H. Arthroscopic double-bundle anterior cruciate ligament reconstruction using autogenous quadriceps tendon. *Arthroscopy* 2006;22:797.e1-797.e5. Available online at [www.arthroscopyjournal.org](http://www.arthroscopyjournal.org).
5. Chhabra A, Kline AJ, Nilles KM, Harner CD. Tunnel expansion after anterior cruciate ligament reconstruction with autogenous hamstrings: A comparison of the medial portal and transtibial techniques. *Arthroscopy* 2006;22:1107-1112.
6. Kobayashi M, Nakagawa Y, Suzuki T, Okudaira S, Nakamura T. A retrospective review of bone tunnel enlargement after anterior cruciate ligament reconstruction with hamstring tendons fixed with a metal round cannulated interference screw in the femur. *Arthroscopy* 2006;22:1093-1099.
7. Brucker PU, Lorenz S, Imhoff AB. Aperture fixation in arthroscopic anterior cruciate ligament double-bundle reconstruction. *Arthroscopy* 2006;22:1250.e1-1250.e6. Available online at [www.arthroscopyjournal.org](http://www.arthroscopyjournal.org).
8. Cohen SB, Fu FH. Three-portal technique for anterior cruciate ligament reconstruction: Use of a central medial portal. *Arthroscopy* 2007;23:325.e1-325.e5. Available online at [www.arthroscopyjournal.org](http://www.arthroscopyjournal.org).
9. Smith PA. An alternative method for "all-inside" anterior cruciate ligament reconstruction. *Arthroscopy* 2007;23:451 (letter).
10. Fu FH, Ranawat A. Tensioning in double-bundle ACL reconstruction. *Arthroscopy* 2007;23:1027 (letter).
11. Zantop T, Kubo S, Petersen W, Musahl V, Fu FH. Current techniques in anatomic anterior cruciate ligament reconstruction. *Arthroscopy* 2007;23:938-947.
12. Kaz R, Starman JS, Fu FH. Anatomic double-bundle anterior cruciate ligament reconstruction revision surgery. *Arthroscopy* 2007;23:1250.e1-1250.e3. Available online at [www.arthroscopyjournal.org](http://www.arthroscopyjournal.org).
13. Frank DA, Altman GT, Re P. Hybrid anterior cruciate ligament reconstruction: Introduction of a new technique for anatomic anterior cruciate ligament reconstruction. *Arthroscopy* 2007;23:1354.e1-1354.e5. Available online at [www.arthroscopyjournal.org](http://www.arthroscopyjournal.org).
14. Siebold R, Dehler C, Ellert T. Prospective randomized comparison of double-bundle versus single-bundle anterior cruciate ligament reconstruction. *Arthroscopy* 2008;24:137-145.
15. Basdekis G, Abisafi C, Christel P. Influence of knee flexion angle on femoral tunnel characteristics when drilled through the anteromedial portal during anterior cruciate ligament reconstruction. *Arthroscopy* 2008;24:459-464.
16. Neven E, D'Hooghe P, Bellemans J. Double-bundle anterior cruciate ligament reconstruction: A cadaveric study on the posterolateral tunnel position and safety of the lateral structures. *Arthroscopy* 2008;24:436-440.
17. Siebold R, Ellert T, Metz S, Metz J. Femoral insertions of the anteromedial and posterolateral bundles of the anterior cruciate ligament: Morphometry and arthroscopic orientation models for double-bundle bone tunnel placement—A cadaver study. *Arthroscopy* 2008;24:585-592.
18. Lee B-I, Kwon S-W, Kim J-B, Choi H-S, Min K-D. Comparison of clinical results according to amount of preserved remnant in arthroscopic anterior cruciate ligament reconstruction using quadrupled hamstring graft. *Arthroscopy* 2008;24:560-568.
19. Baer GS, Fu FH, Shen W, Ekdahl M, Nozaki M, Bonci G. Effect of knee flexion angle on tunnel length and articular cartilage damage during anatomic double-bundle anterior cruciate ligament reconstruction. *Arthroscopy* 2008;24:e31 (suppl, abstr).
20. Christel P, Basdekis G, Abisafi C. The influence of knee flexion for drilling posterolateral femoral tunnels during double-bundle anterior cruciate ligament reconstruction through a medial portal. *Arthroscopy* 2008;24:e30-e31 (suppl, abstr).
21. Myers P, Logan M, Stokes A, Boyd K, Watts M. Bioabsorbable versus titanium interference screws with hamstring autograft in anterior cruciate ligament reconstruction: A prospective randomized trial with 2-year follow-up. *Arthroscopy* 2008;24:817-823.
22. Pombo MW, Shen W, Fu FH. Anatomic double-bundle anterior cruciate ligament reconstruction: Where are we today? *Arthroscopy* 2008;24:1168-1177.
23. Smith PA, Schwartzberg RS, Lubowitz JH. No tunnel 2-socket technique: All-inside anterior cruciate ligament double-bundle retroconstruction. *Arthroscopy* 2008;24:1184-1189.
24. Christel P, Sahasrabudhe A, Basdekis G. Anatomic double-bundle anterior cruciate ligament reconstruction with anatomic aimers. *Arthroscopy* 2008;24:1146-1151.
25. Nakagawa T, Takeda H, Nakajima K, et al. Intraoperative 3-dimensional imaging-based navigation-assisted anatomic double-bundle anterior cruciate ligament reconstruction. *Arthroscopy* 2008;24:1161-1167.

26. Shino K, Nakata K, Nakamura N, Toritsuka Y, Horibe S, Nakagawa S, Suzuki T. Rectangular tunnel double-bundle anterior cruciate ligament reconstruction with bone–patellar tendon–bone graft to mimic natural fiber arrangement. *Arthroscopy* 2008;24:1178-1183.
27. Colombet PD, Robinson JR. Computer-assisted, anatomic, double-bundle anterior cruciate ligament reconstruction. *Arthroscopy* 2008;24:1152-1160.
28. Volpi P, Denti M. Double-bundle reconstruction of the anterior cruciate ligament using the transtibial technique. *Arthroscopy* 2008;24:1190-1194.
29. Siebold R, Fu FH. Assessment and augmentation of symptomatic anteromedial or posterolateral bundle tears of the anterior cruciate ligament. *Arthroscopy* 2008;24:1289-1298.
30. Järvelä T, Moisala A-S, Paakkala T, Paakkala A. Tunnel enlargement after double-bundle anterior cruciate ligament reconstruction: A prospective, randomized study. *Arthroscopy* 2008;24:1349-1357.
31. Lewicky YM. The acorn Beath couple: Articular salvation for double-bundle femoral tunnels in cruciate ligament reconstruction. *Am J Orthop* 2007;36:648-651.